

## DIAGNOSTIC RADIOLOGY TECHNOLOGIST COMPETENCY CHECKLIST

Marker placement for Orthoveiw written: 01/26/11

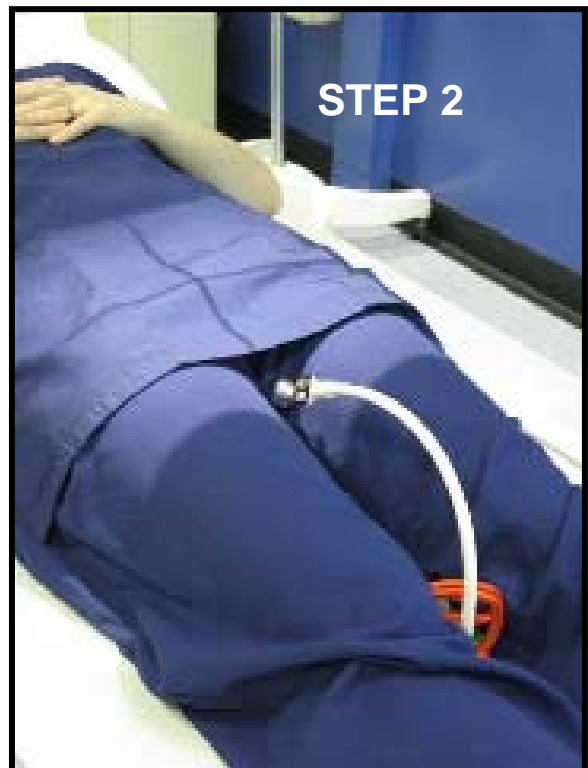
\_\_\_\_\_  
Employee name

\_\_\_\_\_  
date

\_\_\_\_\_  
orientation/assessment given by & date

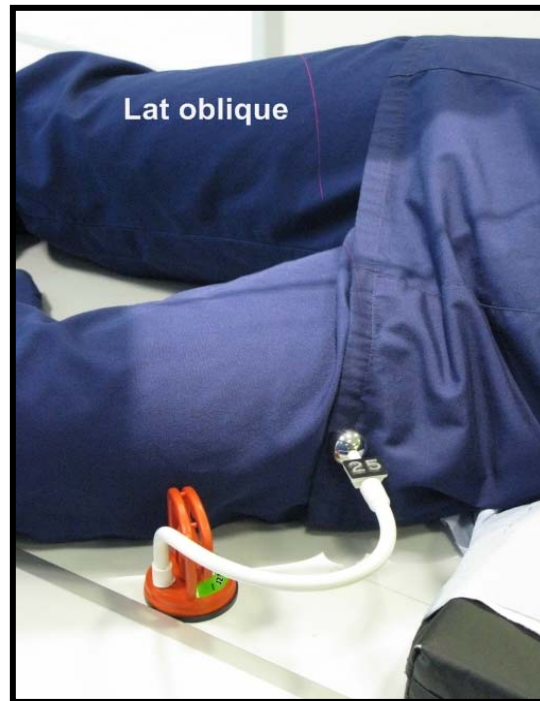
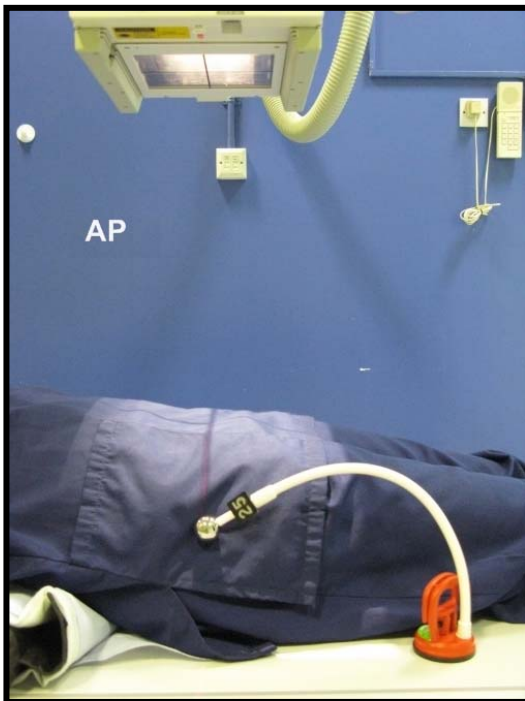
### PELVIS

- Position patient to include upper 1/3 of femoral shaft on the pelvis image
- There are 2 stages for marker positioning on the pelvis image.
  1. Position at the level of the greater trochanter on the lateral side of the pelvis, equivalent to the hip joint level.
  2. Unless the patient is narrow at the hip the marker will be projected beyond the margin of the image. Move the marker carefully to the same vertical height level between the thighs where it will be visible in the radiation field.



## HIP

- AP**—Same positioning as pelvis, at the vertical level/height of the greater trochanter on the lateral side of the hip. Include marker in the radiation field
- LATERAL OBLIQUE**—The marker is placed laterally mid-thigh to best establish the level of the femoral shaft.  
\*\*\*For very large patients any adipose tissue will need to be taken into account.
- LATERAL INFERIOR-SUPERIOR**—Marker is positioned anteriorly mid-thigh to establish femoral canal width only near position of marker.



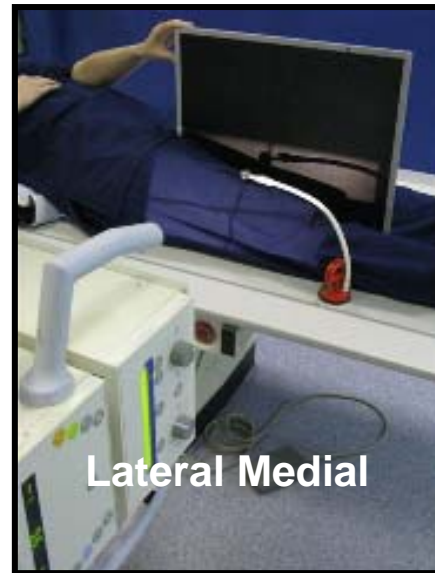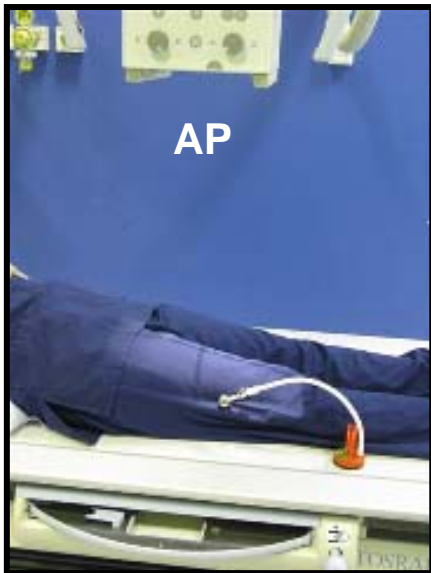
### LONG BONES-FEMUR, ETC.

**AP**—Place the marker midway between anterior and posterior surfaces over the shaft on the lateral side of the bone.

**LATERAL**—

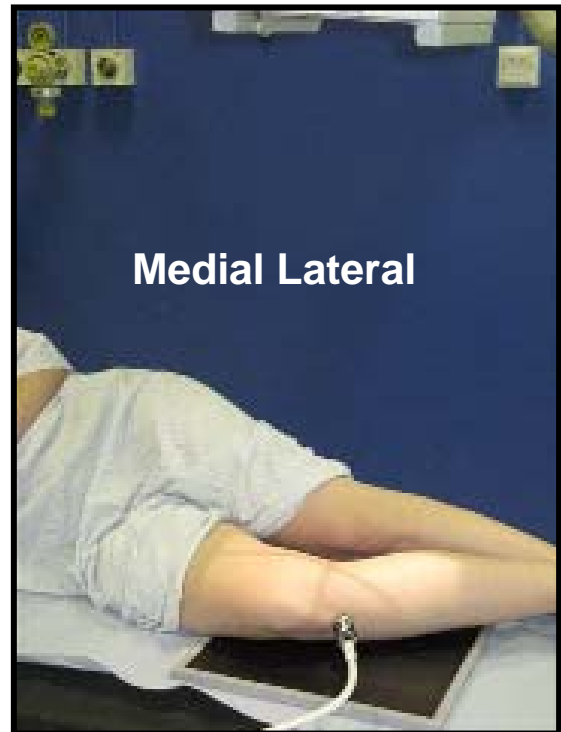
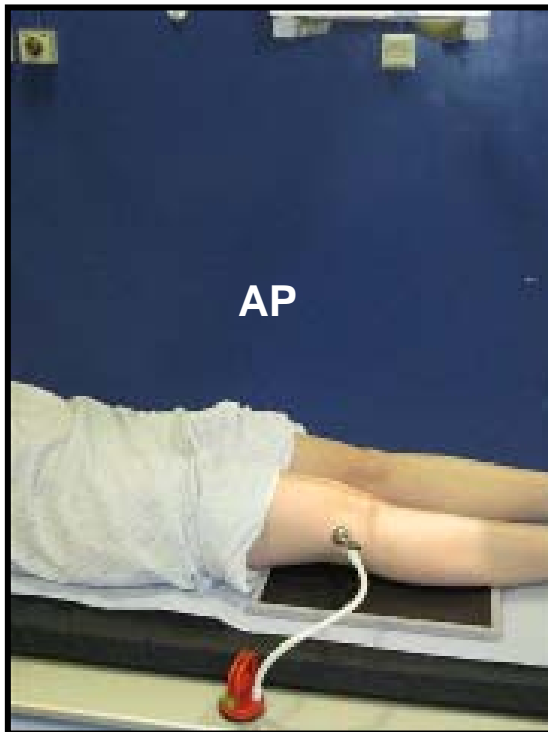
- **MEDIAL-LATERAL**—Place the marker on the anterior part of the limb in the mid-line.
- **LATERAL-MEDIAL**—Place on the anterior mid-line of the limb around the area of interest if known.

\*\*\*As the surgeon will need to know how the lateral was taken-annotate with horizontal beam or LM if possible.



## KNEE

- Position patient so an equal amount of femoral and tibial shaft are visible on the image.
- AP**—Marker is placed over the lateral side of the knee in the joint line, roughly midway between anterior and posterior surfaces, however if a patient is well muscled this needs to be considered.
- MEDIAL-LATERAL**—Marker is placed on the anterior side of the knee, either superior or inferior to patella in the midline.
- LATERAL-MEDIAL**—Place on the anterior mid-line of the knee. Marker positioned just like the lateral medial femur.



### SHOULDER AP

- Marker is placed on the lateral side of the humeral head at the mid-point between the palpable anterior and posterior bony prominences of the acromion to best define the humeral head.



### HUMERUS

- AP**—Marker is placed on the lateral part of the upper arm at the mid-point between the anterior and posterior side.
- LATERAL**—Marker is placed on the posterior side of the upper arm midway between the lateral and medial surfaces of the limb.